

Late-presenting *Plasmodium falciparum* Malaria in a Non-Endemic Setting During COVID-19 Travel Restrictions

LTC Paul M. Robben, MC, USA^{✉*}; MAJ Christopher R. Dunbar, MC, USA[†]; Elgin H. Akin, BS^{*}; Alexander Pichugin, MD, PhD^{*}; COL Jason A. Regules, MC, USA^{*}

ABSTRACT We report a case of febrile *Plasmodium falciparum* malaria in a 36-year-old male patient occurring 14 years after immigration from and more than 12 months since a return visit to the endemic area. The critical need for awareness regarding late presentations of *P. falciparum* is discussed.

INTRODUCTION

Despite decades of intense, coordinated efforts aimed at malaria elimination and eradication, the World Health Organization estimates 229 million cases of malaria occurred in 2019, resulting in 409,000 deaths. Coronavirus disease 2019 (COVID-19)–driven disruptions of malaria control efforts may have resulted in an increase in 19,000–100,000 malaria deaths in sub-Saharan Africa during 2020.¹ The majority of malaria cases diagnosed in the USA are acquired in Africa (91%) and due to *Plasmodium falciparum* (77%).² Migrants from endemic countries, permanently settled in non-endemic countries, who are “visiting friends and relatives” (VFRs) during return visits to their country of origin are one of the highest-risk groups for presenting with imported malaria.^{2,3} Although *P. falciparum* infection in nonimmune travelers typically results in clinical malaria within 1–2 months of departing an endemic region,⁴ semi-immune migrants are at risk of delayed presentations.^{5–7}

We report a case of *P. falciparum* malaria occurring more than 1 year after the last possible exposure in the setting of COVID-19-related travel restrictions. The case emphasizes the challenge *P. falciparum* represents and the need for clinician vigilance when assessing VFRs presenting outside typical incubation periods, particularly in light of lingering questions regarding the maintenance of naturally acquired immunity.

CASE REPORT

In January 2021, a 36-year-old active duty male service member was admitted to Dwight D. Eisenhower Army Medical

Center (Fort Gordon, GA, USA) for a 7-day history of fevers, headache, malaise and exertional dyspnea. Prior outpatient evaluations primarily focused on ensuring rapid detection of COVID-19 due to the nonspecific nature of his symptoms and lack of physical examination findings suggestive of other focal infection. He tested negative for severe acute respiratory syndrome coronavirus 2 (SARS-CoV-2) on three separate occasions (nasopharyngeal swab polymerase chain reaction on days 1 and 7 and nasopharyngeal SARS-CoV-2 antigen test on day 5). He was admitted (day 7) when his febrile episodes did not resolve and laboratory evaluations revealed leukopenia (white blood cell count 3.6×10^9 cells/L), normochromic, normocytic anemia (Hb 112 g/L), and thrombocytopenia (35×10^9 platelets/L). The patient reported immigrating to the USA from Cameroon in 2006. He had visited Cameroon every 1–2 years since, with the most recent visit being of 4-week duration 13 months before presentation. He denied using malaria chemoprophylaxis during these visits and further denied any history of fevers or malaria treatment after his immigration. He denied travel to any other malaria-endemic region or a history of transfusion. Review of his medical records revealed the presence of sickle cell trait. At admission, he was febrile to 39.0 °C, consistent with the twice-daily fevers he reported occurring before admission. Physical examination was notable for tachycardia to 126 beats per minute, but otherwise unremarkable. Serum electrolytes, creatinine, and liver enzyme levels were all within normal limits. The erythrocyte sedimentation rate (33 mm/h), D-dimer (2.87 mg/L), and fibrinogen (5.35 g/L) were elevated. Serum haptoglobin undetectable at <80 mg/L, lactate dehydrogenase 459 U/L, total bilirubin 0.25 g/L, and urinalysis with elevated urobilinogen (40 mg/L) suggested intravascular hemolysis, and direct antiglobulin testing was negative arguing against an autoimmune etiology. Surprisingly, a rapid malaria antigen test (BinaxNow Malaria; Alere Scarborough, Inc., Scarborough, ME, USA) was positive for *P. falciparum* (Fig. 1B). Microscopic examination of initial thick and thin blood smears from a specimen collected during an afebrile period did not reveal the presence of malaria. A subsequent specimen collected when the patient was febrile revealed parasitemia 0.7% with intracellular ring stage *Plasmodium* trophozoites without a formal species identification, but most

*Malaria Biologics Branch, Walter Reed Army Institute of Research, Silver Spring, MD 20910, USA

†Infectious Disease Service, Dwight D. Eisenhower Army Medical Center, Fort Gordon, GA 30905, USA

The opinions or assertions contained herein are the private views of the authors and are not to be construed as official or reflecting the views of the Department of the Army, the Defense Health Agency, the Department of Defense, or the U.S. Government. This work was prepared as part of their official duties; and, as such, there is no copyright to be transferred.

doi:https://doi.org/10.1093/milmed/usab393

Published by Oxford University Press on behalf of the Association of Military Surgeons of the United States 2021. This work is written by (a) US Government employee(s) and is in the public domain in the US.

consistent with *P. falciparum* (Fig. 1A). The patient was treated with atovaquone/proguanil 1,000/400 mg once daily for 3 days. Within 24 hours he enjoyed resolution of fever, headache, and malaise and reported improvement in fatigue and dyspnea. After confirming the absence of glucose-6-phosphate dehydrogenase (G6PD) deficiency, presumptive antirelapse therapy was provided given the residual question of a mixed infection with *Plasmodium ovale* or *Plasmodium vivax*⁸ and the patient was discharged. Quantitative reverse transcription polymerase chain reaction^{9,10} was performed on a stored blood sample collected approximately 24 h after initiation of atovaquone/proguanil therapy. Positive results were obtained for pan-*Plasmodium* spp. and *P. falciparum*-specific primers, with C_t values supporting an estimated $15,219 \pm 396$ parasites/ μ L of blood, corresponding to a parasitemia of 0.46%. *P. ovale*, *P. vivax*, and *Plasmodium malariae* were not detected. Review of all thick and thin smears did not demonstrate evidence to support coinfection with *P. ovale*, *P. malariae*, or *P. vivax*. At follow-up the patient was fully recovered and repeat thick and thin blood smears have remained negative.

DISCUSSION

Plasmodium falciparum remains one of the leading causes of potentially life-threatening illness in febrile returning travelers and a main cause of death.⁴ Clinician's recognition of *P. falciparum* infection in non-endemic areas is of critical importance as delays in diagnosis and treatment contribute to an increased risk of developing severe disease.¹¹ An accurate travel history is usually the key to making the diagnosis of malaria¹² but clinicians must recognize that migrant patients in particular may present far outside the routinely quoted incubation periods for *P. falciparum* and the other malarias.⁵ The discordance between the often delayed clinical presentation in migrants from endemic regions and the incubation patterns that must be relied upon to guide the recognition of malaria in malaria-naïve individuals is of considerable significance in light of immigrant VFRs more recently representing the majority of individuals diagnosed with malaria in non-endemic countries.² Moreover, for members of the U.S. Military forces, immigrant VFRs (particularly those born in countries in western Africa) were found to represent a significant portion of malaria diagnoses and to be among the highest-risk groups for presenting with malaria.¹³

The duration of our patient's *P. falciparum* infection before his presentation cannot be definitively determined. With no history of transfusion, occupational exposure, or evidence of autochthonous transmission, the patient acquired the infection with high certainty during time spent in endemic Cameroon. His last travel to the region was shortly before the institution of COVID-19 travel restrictions, confidently establishing a minimum of 13-month duration for his infection before symptom onset. Alternatively, our patient may have acquired an asymptomatic infection during an earlier (but not his most recent) VFR visit to Cameroon. This possibility highlights ongoing

uncertainty regarding the durability of naturally acquired immunity in individuals who have departed endemic regions. It is well established that the ability of individuals to control their parasitemia at low levels without symptoms results from the slow acquisition of immunity following repeated or protracted exposure over years, and naturally acquired immunity dissipates without continued exposure.^{2,12} Although the rate of such decline and subsequent clinical impact is not defined,² presumably our patient's ability to acquire a clinically asymptomatic infection was diminished at each subsequent visit if he had not been infected previously. In theory, the patient could have been carrying a *P. falciparum* infection since his immigration 14 years before presentation consistent with his denial of any prior episodes of symptomatic malaria or receipt of antimalarials for treatment or chemoprophylaxis during the post-immigration period. Dauby et al.⁵ reported a median of 3 years between the last stay in an endemic region and the onset of clinical malaria among migrants presenting in non-endemic settings. Their literature review identified a maximum duration of 10 years in two separate cases. Similarly, Ashley et al.¹⁴ systematically identified reported cases of *P. falciparum* infection with delayed presentations, and falciparum malaria transmitted via transfusion or transplant more than 6 months after the donor left an endemic region. The median duration of infection was 3 years and slightly less than 2 years, respectively, with the longest duration calculated as 13-17 years in one instance and possibly 15 years in another, lending credence to the possibility that our patient may have presented after infection 14 years prior.

Host genetic factors influence the severity of malaria infections. The strongest protective effect against severe malaria conferred by a hemoglobin variant results from heterozygous carriage of HbS (sickle cell trait), followed by homozygous α -thalassemia.¹⁵ Our patient's HbAS status augmented his ability to maintain an asymptomatic infection, and relatively low parasitemia after symptoms developed, but thalassemia was ruled out via the hemoglobin electrophoresis results that established his HbAS status. Notably, he possesses O blood group which is also associated with diminished malaria severity.¹⁵ Other polymorphisms known to be protective against some manifestations of severe *P. falciparum* infection were either not present (G6PD deficiency) or deemed unlikely (e.g., Dantu blood group, only found regularly in East African populations) or unknown (e.g., complement receptor 1 polymorphism).

Although *P. falciparum* is responsible for 95% of malaria infections in Cameroon,⁸ the patient's delayed presentation was, more conventionally, suggestive of *P. ovale* or *P. vivax* relapse. This case illustrates the difficulty of ruling out mixed infections. Rare *P. ovale* or *P. vivax* parasites may be missed during microscopic examination of blood smears containing predominantly *P. falciparum*, and the decreased sensitivity of rapid malaria antigen tests for *P. vivax* and *P. ovale* results in a significant risk of infections that fall below the limit of

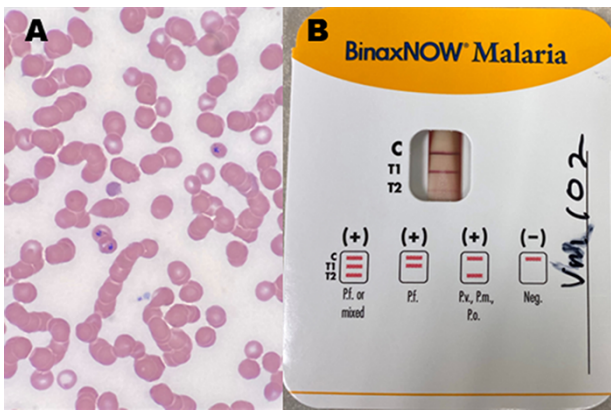


FIGURE 1. Clinical laboratory specimens. (A) Immature *Plasmodium falciparum* trophozoites visible in infected erythrocytes in a Wright-stained peripheral blood smear of a specimen collected from the patient. (B) *Plasmodium falciparum*-positive rapid diagnostic test performed on a patient specimen.

detection. In this case where the patient’s G6PD status was already established it was felt prudent to provide antirelapse therapy with primaquine which the patient tolerated without issue.

This case of a patient presenting symptomatically with *P. falciparum* malaria in a non-endemic setting, in the midst of an ongoing COVID-19 pandemic, more than 1 year after the last possible exposure and potentially up to 14 years after the initial infection, highlights challenges malaria poses for the healthcare system. No combination of clinical signs or symptoms is reliably diagnostic for malaria, so clinicians must remain alert to the possible diagnosis and aware that delayed presentations can occur, particularly in individuals with significant prior exposure. Furthermore, mixed infections are common, but can be difficult to rule out, necessitating a comprehensive approach to diagnosis, treatment, and follow-up.

ACKNOWLEDGMENT

None declared.

FUNDING

None declared.

CONFLICT OF INTEREST STATEMENT

None declared.

REFERENCES

1. World malaria report 2020: 20 years of global progress and challenges. 2020, p 299. Available at <https://apps.who.int/iris/rest/bitstreams/1321872/retrieve>; accessed April 19, 2021.
2. Mischlinger J, Ronnberg C, Alvarez-Martinez MJ, et al: Imported malaria in countries where malaria is not endemic: a comparison of semi-immune and nonimmune travelers. Clin Microbiol Rev 2020; 33(2): e00104–19.
3. Schlagenhauf P, Patel D: Who, where, and why: moves to checkmate imported malaria? Clin Infect Dis 2019; 69(7): 1163–4.
4. Thwaites GE, Day NP: Approach to fever in the returning traveler. N Engl J Med 2017; 376(6): 548–60.
5. Dauby N, Figueiredo Ferreira M, Konopnicki D, Nguyen VTP, Cantinieaux B, Martin C: Case report: delayed or recurrent Plasmodium falciparum malaria in migrants: a report of three cases with a literature review. Am J Trop Med Hyg 2018; 98(4): 1102–6.
6. Szmítko PE, Kohn ML, Simor AE: Plasmodium falciparum malaria occurring 8 years after leaving an endemic area. Diagn Microbiol Infect Dis 2009; 63(1): 105–7.
7. Pennington K, Ives ST, Frosch AEP, Shaughnessy MK: Delayed clinical presentation of Plasmodium falciparum malaria after leaving an endemic area: a tale of two patients. J Travel Med 2020; 27(6): taaa092.
8. Antonio-Nkondjio C, Ndo C, Njiokou F, et al: Review of malaria situation in Cameroon: technical viewpoint on challenges and prospects for disease elimination. Parasit Vectors 2019; 12(1): 501.
9. Kamau E, Alemayehu S, Feghali KC, et al: Measurement of parasitological data by quantitative real-time PCR from controlled human malaria infection trials at the Walter Reed Army Institute of Research. Malar J 2014; 13: 288.
10. Vo TKD, Bigot P, Gazin P, et al: Evaluation of a real-time PCR assay for malaria diagnosis in patients from Vietnam and in returned travellers. Trans R Soc Trop Med Hyg 2007; 101(5): 422–8.
11. Mousa A, Al-Taiar A, Anstey NM, et al: The impact of delayed treatment of uncomplicated P. falciparum malaria on progression to severe malaria: a systematic review and a pooled multicentre individual-patient meta-analysis. PLoS Med 2020; 17(10): e1003359.
12. Ashley EA, Pyae Phyo A, Woodrow CJ: Malaria. Lancet 2018; 391(10130): 1608–21.
13. Wertheimer ER, Brundage JF, Fukuda MM: High rates of malaria among US military members born in malaria-endemic countries, 2002–2010. Emerg Infect Dis 2011; 17(9): 1701–3.
14. Ashley EA, White NJ: The duration of Plasmodium falciparum infections. Malar J 2014; 13: 500.
15. Kariuki SN, Williams TN: Human genetics and malaria resistance. Hum Genet 2020; 139(6–7): 801–11.

Downloaded from <https://academic.oup.com/milmed/article/188/5-6/e1335/6374774> by guest on 22 August 2024